

Cerebral White-Matter Lesions in Asymptomatic Military Divers

ICLAL ERDEM, SENOL YILDIZ, GUNALP UZUN, GUNER SONMEZ, MEHMET GUNEY SENOL, MESUT MUTLUOGLU, HAKAN MUTLU, AND BULENT ONER

ERDEM I, YILDIZ S, UZUN G, SONMEZ G, SENOL MG, MUTLUOGLU M, MUTLU H, ONER B. *Cerebral white-matter lesions in asymptomatic military divers*. *Aviat Space Environ Med* 2009; 80:2-4.

Introduction: There is some concern that over a period of years, diving may produce cumulative neurological injury even in divers who have no history of decompression sickness. We evaluated asymptomatic divers and controls for cerebral white-matter lesions using magnetic resonance imaging (MRI). **Methods:** The study enrolled 113 male military divers (34.4 ± 5.6 yr) and 65 non-diving men (33.1 ± 9.0 yr) in good health. Exclusion criteria included any condition that might be expected to produce neurological effects. Patent foramen ovale was not assessed. A questionnaire was used to elicit diving history. A 1.5-T MRI device was used to acquire T1, T2-weighted, and fluid attenuated inversion recovery (FLAIR) images of the brain. A lesion was counted if it appeared hyperintense on both T2-weighted and FLAIR images. **Results:** MRI revealed brain lesions in 26 of 113 divers (23%) and in 7 of 65 (11%) controls, a difference that was statistically significant. There was no significant difference between the groups with respect to blood pressure, smoking history, or alcohol consumption, and no subject reported a history of head trauma or migraine. There was no relationship between MRI findings and age, diving history, or lipid profile in divers. **Discussion:** The higher incidence of lesions in the cerebral white matter of divers confirms the possibility that cumulative, subclinical injury to the neurological system may affect the long-term health of military and recreational divers.

Keywords: hyperintense lesion, military diver, long term, magnetic resonance imaging.

WITH THE POPULARITY of recreational diving, the possible long-term health consequences of such activity have become an issue of increasing interest. Dysbaric osteonecrosis, hearing loss, and neurological deficits due to decompression sickness (DCS) have long been recognized as potential sequelae. However, concerns have recently emerged concerning subclinical brain lesions in divers with no history of symptomatic DCS (13).

Although the mechanism of DCS is not fully understood, it is generally accepted that evolved gas bubbles in the tissues and the circulation are the underlying mechanism. Bubbles may impair tissue functions by causing either biochemical or mechanical damage (12). The central nervous system (CNS) appears to be a common place for the acute manifestations of DCS, a theory that is supported by histopathological studies (1). Doppler ultrasonography shows that bubbles often occur after dives even in the absence of symptoms (4), and it is suggested that such "silent" bubbles could produce subclinical brain lesions in divers with no history of DCS (13).

Several studies have been performed to investigate the incidence of brain lesions in divers (2,3,5-7,9). The exact mechanism of subclinical brain lesions has not been clearly established; the pathogenesis appears to involve various factors, including age, head injury, alcohol consumption, migraine, smoking, hypertension, high blood cholesterol, infection, and patent foramen ovale. In this study we evaluated asymptomatic military divers and non-diving controls for cerebral white matter lesions by using magnetic resonance imaging (MRI).

METHODS

This study was part of a cross-sectional study on the long-term negative effects of diving on Turkish Navy divers (11). The study protocol was approved by Gulhane Military Medical Academy Ethics Committee. Subjects gave their written informed consent for participation. The study included a total of 113 male military divers on active duty recruited from the Turkish Naval Forces Underwater and Salvage Command, Istanbul, Turkey. None of them had a history of DCS; a questionnaire was used to obtain their diving histories, including years of diving, maximum diving depth, frequent diving depth, and missed decompression. Controls were 65 age-matched male non-divers who were referred to the MRI unit for various musculoskeletal disorders such as lumbar disc hernia.

A questionnaire was administered to all potential subjects (divers and controls) to obtain a medical history including past and current diseases, smoking habits, and alcohol intake. Physical examination and laboratory testing included blood pressure, complete blood count, erythrocyte sedimentation rate, serum cholesterol, tri-

From the Department of Radiology, Taksim Teaching and Research Hospital, Taksim, Istanbul, Turkey; and the Department of Underwater and Hyperbaric Medicine, Department of Radiology, and Department of Neurology, Gulhane Military Medical Academy, Haydarpasa Teaching Hospital, Istanbul, Turkey.

This manuscript was received for review in November 2007. It was accepted for publication in October 2008.

Address reprint requests to: Senol Yildiz, M.D., GATA Haydarpasa, Egitim Hastanesi Sualti ve Hiperbarik Tip Servisi, 34668 Kadikoy, Istanbul, Turkey; senoyildiz@yahoo.com.

Reprint & Copyright © by the Aerospace Medical Association, Alexandria, VA.

DOI: 10.3357/ASEM.2234.2009

glyceride, low-density lipoprotein, high-density lipoprotein, aspartate transaminase, alanine transaminase, uric acid, glucose level, and urine analysis. Normal values for lipids were as follows: cholesterol 125–240, high density lipoprotein (HDL) 45–70, low density lipoprotein (LDL) 65–160, and triglycerides 50–150. No testing was done to detect patent foramen ovale.

Exclusion criteria for all subjects included cardiovascular disease, diabetes, hypertension, multiple sclerosis, or vascular brain disease. As navy divers are subject to strict periodic medical examination and have normal blood pressures and lipid levels, we excluded from the control group men with either hypertension or hyperlipidemia. The requirement that all subjects undergo MRI dictated exclusion of anyone with claustrophobia or a pacemaker.

MRI was done by using a 1.5-Tesla magnetic resonance scanner (Magnetom vision, Siemens, Erlangen, Germany) equipped with a head coil. T1- and T2-weighted images were acquired from all subjects. In addition, fluid attenuated inversion recovery (FLAIR) images were also obtained to improve differentiation between widened perivascular (Virchow-Robin) spaces and true brain lesions. Images were reviewed by two radiologists blinded to the study groups. A lesion was counted if it was hyperintense on both T2-weighted and FLAIR images.

The data are expressed as percentages for categorical variables and as mean \pm SD for continuous variables. Divers and controls were compared by using Student *t*-test for continuous variables, and Fisher's exact test for categorical variables. Divers were grouped according to the presence of hyperintense brain lesions (HIBL) to analyze the relationship between HIBL and age, lipid profiles, and diving characteristics. All statistical analyses were carried out with the SPSS software package (version 10.0, SPSS, Chicago, IL). Statistical significance was set at $P < 0.05$.

RESULTS

The ages of divers and controls were 34.4 ± 5.6 yr (range: 23–49 yr) and 33.1 ± 9.0 yr (range: 20–49 yr), respectively ($P > 0.05$). MRI revealed HIBL in 26 divers (23%) and in 7 controls (11%) ($P = 0.043$). Mean triglyceride, HDL cholesterol, LDL cholesterol, and total cholesterol levels for the divers were: 107 ± 58 mg \cdot dl⁻¹, 52 ± 9 mg \cdot dl⁻¹, 125 ± 31 mg \cdot dl⁻¹, and 182 ± 42 mg \cdot dl⁻¹,

respectively. Equivalent levels for the controls were 109 ± 31 mg \cdot dl⁻¹, 55 ± 11 mg \cdot dl⁻¹, 121 ± 34 mg \cdot dl⁻¹, and 173 ± 35 mg \cdot dl⁻¹, respectively. There was no significant difference between divers and controls in terms of lipid levels ($P > 0.05$).

Although all divers reported that they occasionally drank alcohol, none of them had a habit of regular alcohol intake. Five of the controls reported to have never drunk alcohol, while the remaining controls reported occasional alcohol intake. Smoking was reported by 21% of the divers and 41% of the controls, with no significant difference in terms of pack-years. Neither divers nor controls reported a history of migraine or head injury. Blood pressure readings were 123/73 mmHg for divers and 126/69 mmHg for controls, with no statistical significance. The diving histories provided the following values for mean \pm SD: years in occupation 12.2 ± 6.0 (range: 1–25); total hours of diving 857 ± 464 (range: 100–2100); maximum diving depth in meters 52.7 ± 18.4 (range: 35–109); and frequent diving depth 13.2 ± 8.3 (range: 6–51).

Fig. 1 shows an example of MRI images from a diver who was found to have HIBL. Of such divers, four (15%) had triglyceride levels higher than 150 mg \cdot dl⁻¹, two (7%) had LDL > 160 mg \cdot dl⁻¹, and none had high total cholesterol. The equivalent values for divers without brain lesions were seven (8%) with triglyceride > 150 mg \cdot dl⁻¹, four (5%) with LDL > 160 mg \cdot dl⁻¹, and eight (9%) with > 240 mg \cdot dl⁻¹ total cholesterol. There was no significant relationship between MRI findings and age, diving characteristics, or lipid profile in divers.

DISCUSSION

The hypothesis that HIBL are a consequence of diving has been debated for many years and there is disagreement among previous studies of this issue. In this study, we found a significantly higher incidence of HIBL in divers compared to controls. Several previous studies report results that agree with ours. Fueredi et al. (2) studied 19 compressed-air workers and found 152 HIBL in 10 of them (53%) vs. 22 lesions in 2 of 11 controls (18%). Reul et al. (5) reported 86 HIBL in 27 out of 52 sport divers (52%) compared to 14 lesions in 10 out of 50 controls (20%). These studies have all been criticized for the lack of FLAIR sequences for evaluation with the T2 images. Schwerzmann et al. (7) found similar results to those of Reul et al. and Fueredi et al. They reported HIBL

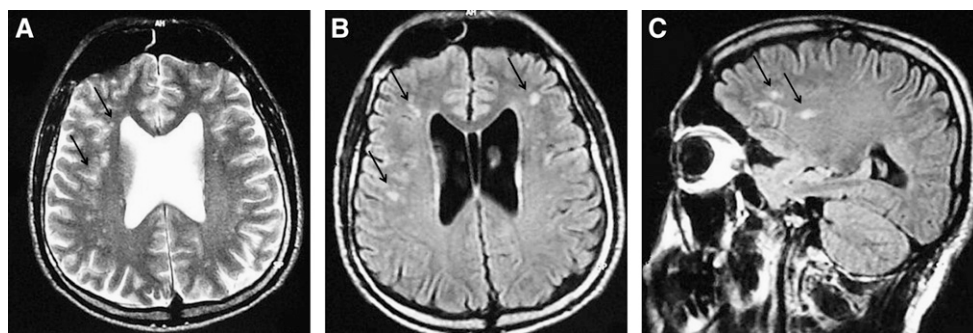


Fig. 1. Multiple hyperintense gliotic lesions in the periventricular area in a 43-yr-old military diver diving for 19 yr. A) T2-weighted axial image, B) axial, and C) sagittal FLAIR sequences.

in 19 of 43 asymptomatic divers (44%) compared to 6 of 52 controls (12%).

However, other studies reported opposite results. Rinck et al. (6) found a higher prevalence of HIBL in controls compared to divers (43% and 34%, respectively). Todnem et al. (9) reported significantly higher HIBL in controls compared to divers (43% and 19%, respectively). Hutzelman et al. (3) found HIBL in 48% of controls compared to 37% with HIBL in divers.

Todnem et al. postulated that a positive correlation existed between age and the HIBL in divers (9). We did not find a significant relationship between age and MRI findings in divers. Tetzlaff et al. (8) found HIBL in 60% of elderly compressed air divers without a DCS history and in 45% of non-diving controls. The difference between his results and ours may be attributable to age, mean 34 yr in our divers vs. 50 yr in Tetzlaff's study. Indeed, Todnem et al. found 33% with abnormalities in the MRI of their divers who had a mean age of 33.6 yr (9). This later is closer to our findings. Our divers were from a special unit of the navy and as they experienced strict performance tests and meticulous physical examination before being admitted to the navy, this could be another explanation for the lower percentage of CNS lesions in our study.

Tripodi et al. showed that there is a correlation between blood cholesterol level and cerebral white-matter lesions in sport divers (10). We also analyzed the data for such a relationship in the military divers. Contrary to our expectations, abnormal lipid values were found in 17 of the divers as follows: high triglyceride values in 11 (9%), high cholesterol in eight (7%), high LDL in six (5%), and low HDL in three (2%). We included these divers in the study to examine the possible relationship between cerebral white-matter lesions and abnormal lipid values, but no correlation was found.

We found no significant relationship between HIBL and diving experience, total hours of diving, maximum diving depth, or frequent diving depth in divers. While we detected a significantly elevated incidence of cerebral white-matter lesions in asymptomatic divers compared to controls, in the absence of detailed neurophysiological testing we do not know whether or not the lesions

have clinical consequences. Further studies combining neurophysiological tests and MRI would allow a better understanding of the long-term effects of diving on the CNS.

ACKNOWLEDGMENTS

Authors and affiliations: Iclal Erdem, M.D., and Bulent Oner, M.D., Department of Radiology, Taksim Teaching and Research Hospital, Taksim, Istanbul, Turkey; Senol Yildiz, M.D., Gunalp Uzun, M.D., and Mesut Mutluoglu, M.D., Department of Underwater and Hyperbaric Medicine, Guner Sonmez, M.D., and Hakan Mutlu, M.D., Department of Radiology, and Mehmet Guney Senol, M.D., Department of Neurology, Gulhane Military Medical Academy, Haydarpasa Teaching Hospital, Kadikoy, Istanbul, Turkey.

REFERENCES

1. Calder I. Does diving damage your brain? *Occup Med (Lond)* 1992; 42:213-4.
2. Fueredi GA, Czarnecky DJ, Kindwall EP. MR findings in the brains of compressed air tunnel workers: relationship to psychometric results. *AJNR Am J Neuroradiol* 1991; 12:67-70.
3. Hutzelman A, Tetzlaff K, Reuter M, Müller-Hülsbeck S, Heller M. Does diving damage the brain? MR control study of divers' central nervous system. *Acta Radiol* 2000; 41:18-21.
4. Nishi RY. Doppler and ultrasonic bubble detection. In: Bennett PB, Elliott DH, eds. *The physiology and medicine of diving*, 4th ed. London: Saunders; 1993:433-53.
5. Reul J, Weis J, Jung A, Willmes K, Thron A. Central nervous system lesions and cervical disc herniations in amateur divers. *Lancet* 1995; 345:1403-5.
6. Rinck PA, Svihus R, de Francisco P. MR imaging of the central nervous system in divers. *J Magn Reson Imaging* 1991; 1:293-9.
7. Schwerzmann M, Seiler C, Lipp E, Guzman R, Lovblad KO, Kraus M, et al. Relation between directly detected patent foramen ovale and ischemic brain lesions in sport divers. *Ann Intern Med* 2001; 134:21-4.
8. Tetzlaff K, Friege L, Hutzelman A, Reuter M, Holl D, Leplow B. Magnetic resonance signal abnormalities and neuropsychological deficits in elderly compressed-air divers. *Eur Neurol* 1999; 42:194-9.
9. Todnem R, Nyland H, Skeidsvoll H, Svihus R, Rinck P, Kambestad BK, et al. Neurological long term consequences of deep diving. *Br J Ind Med* 1991; 48:258-66.
10. Tripodi D, Dupas B, Potiron M, Louvet S, Geraut C. Brain magnetic resonance imaging, aerobic power, and metabolic parameters among 30 asymptomatic scuba divers. *Int J Sports Med* 2004; 25:575-81.
11. Uzun G, Toklu AS, Yildiz S, Sonmez G, Aktas S, Sezer H, et al. Dysbaric osteonecrosis screening in Turkish Navy divers. *Aviat Space Environ Med* 2008; 79:44-6.
12. Vann RD, Thalmann ED. Decompression physiology and practice. In: Bennett PB, Elliott DH, eds. *The physiology and medicine of diving*, 4th ed. London: Saunders; 1993:376-432.
13. Wilmshurst P. Brain damage in divers. *BMJ* 1997; 314:689-90.